



CHICAGO JOURNALS



Use of Gaseous Ozone for Eradication of Methicillin-Resistant *Staphylococcus aureus* From the Home Environment of a Colonized Hospital Employee •

Author(s): Hero E. L. de Boer , MD; Carla M. van Elzelingen-Dekker , BSc;

Cora M. F. van Rheenen-Verberg , BSc; Lodewijk Spanjaard , MD, PhD

Source: *Infection Control and Hospital Epidemiology*, Vol. 27, No. 10 (October 2006), pp. 1120-1122

Published by: [The University of Chicago Press](#) on behalf of [The Society for Healthcare Epidemiology of America](#)

Stable URL: <http://www.jstor.org/stable/10.1086/507966>

Accessed: 13/05/2014 20:39

Your use of the JSTOR archive indicates your acceptance of the Terms & Conditions of Use, available at <http://www.jstor.org/page/info/about/policies/terms.jsp>

JSTOR is a not-for-profit service that helps scholars, researchers, and students discover, use, and build upon a wide range of content in a trusted digital archive. We use information technology and tools to increase productivity and facilitate new forms of scholarship. For more information about JSTOR, please contact support@jstor.org.



The University of Chicago Press and The Society for Healthcare Epidemiology of America are collaborating with JSTOR to digitize, preserve and extend access to *Infection Control and Hospital Epidemiology*.

<http://www.jstor.org>

CONCISE COMMUNICATION

Use of Gaseous Ozone for Eradication of Methicillin-Resistant *Staphylococcus aureus* From the Home Environment of a Colonized Hospital Employee

Hero E. L. de Boer, MD;
Carla M. van Elzelingen-Dekker, BSc;
Cora M. F. van Rheenen-Verberg, BSc;
Lodewijk Spanjaard, MD, PhD

An intensive care nurse with eczema was repeatedly treated for methicillin-resistant *Staphylococcus aureus* (MRSA) carriage. Because cultures remained positive for MRSA, her house was investigated. Thirty-four percent of environmental samples yielded MRSA. Her children and cat were free of MRSA. The house was decontaminated with gaseous ozone. All subsequent cultures were negative for MRSA. This decontamination cost €2,000 (approximately \$2,400).

Infect Control Hosp Epidemiol 2006; 27:1120-1122

In most countries, methicillin-resistant *Staphylococcus aureus* (MRSA) is widespread in hospitals. In The Netherlands, national policy is to keep the prevalence of MRSA at the current level of less than 1% of all *S. aureus* isolates.¹ Because hospital employees' hands are an important route of transmission of MRSA, cultures are regularly collected from staff in contact with an MRSA-colonized patient to identify carriage. Employees carrying MRSA are treated with a variety of measures, including administration of mupirocin nasal ointment, chlorhexidine scrub, and orally administered antimicrobial agents. Failure to eradicate carriage is often associated with a risk factor (eg, eczema or wounds), but reinfection after successful eradication also occurs. A possible source of MRSA outside hospitals is the home environment, including family members, pets, and surfaces of furniture. We could not find a published report of disinfection of rooms and furniture with ozone, which is often used as an industrial disinfectant but infrequently tested for possible medical applications.²⁻⁶ This report describes the successful use of gaseous ozone to eradicate MRSA in the home environment, which was responsible for repeated infection of a nurse with eczema who had received several treatments.

CASE REPORT

In December 2001, cultures of specimens from a pediatric intensive care patient unexpectedly yielded MRSA (phage type I64). By E-test (AB Biodisk), the strain was susceptible to tetracycline (minimal inhibitory concentration [MIC], 0.094 mg/L), trimethoprim-sulfamethoxazole (MIC, 0.75 + 14.25 mg/L), vancomycin (MIC, 1.5 mg/L), rifampin (MIC, <0.016

mg/L), and linezolid (MIC, 0.75 mg/L), and was susceptible to mupirocin by disk diffusion; the strain was resistant to oxacillin (MIC, 24 mg/L) and erythromycin (MIC, 16 mg/L) by E-test, and to clindamycin by disk diffusion test (dissociated resistance). The other patients on the ward and the personnel involved with her care were screened for MRSA. In our institution, a set of screening cultures includes at least nose, throat, and perineum swab specimens and, for persons with eczema or skin lesions, a skin swab specimen. Two other patients and 2 nurses carried the same strain of MRSA. After 8 weeks, all colonized patients had been discharged and 1 nurse had multiple cultures negative for MRSA.

Cultures of additional swab specimens of the nose and skin lesions from the other nurse remained positive for MRSA (Figure). She had constitutional eczema with continually fluctuating activity, which was treated with several creams. MRSA eradication treatment was initiated (Figure). In our institution, this approach is only attempted when eczema is quiescent. The initial culture after the initiation of MRSA eradication treatment was negative for MRSA, but later cultures revealed continuing carriage. Three additional courses of anti-MRSA treatment were prescribed. Antimicrobial agents used in the 5 courses of treatment (the duration of all treatments was 7 days) were as follows: courses 1 and 3, mupirocin nasal ointment, chlorhexidine scrub, and vancomycin (250 mg orally every 6 hours); course 2, mupirocin nasal ointment, chlorhexidine scrub, vancomycin (250 mg orally every 6 hours), rifampin (600 mg orally every 24 hours), and doxycycline (100 mg orally every 24 hours); and courses 4 and 5, mupirocin nasal ointment, chlorhexidine scrub, vancomycin (250 mg orally every 6 hours), doxycycline (100 mg orally every 24 hours), and linezolid (600 mg orally every 12 hours).

Because the nurse had persistent MRSA colonization, retraining for another post was considered. She became depressed because of the threat of a switch from her favored occupation and was treated with antidepressants. After the fourth course of anti-MRSA treatment, results of 3 weekly culture sets were negative, and she returned to work in October 2002. However, screening cultures were positive for MRSA a month later. All MRSA isolates from the nurse showed the same susceptibility pattern, as did the isolates from the index patient, the contact patients, and the other nurse. The possibility of reinfection in the home was considered, and environmental screening of her house was performed 2 weeks later. Thirty-two sites in the house were sampled using sweep plates containing mannitol salt agar with 2 mg/L of oxacillin. In addition, swab specimens from her 2 children (nose, throat, and perineum specimens) and her cat (throat, perineum, and coat specimens) were obtained. Eleven (34%) of the environmental cultures yielded MRSA (Table). Her children and the cat tested negative for MRSA.

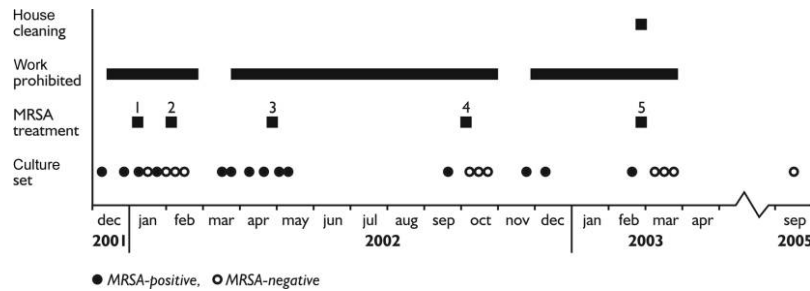


FIGURE. Culture results for the nurse colonized with methicillin-resistant *Staphylococcus aureus* (MRSA) and control measures used, December 2001 to September 2005.

A salvage company was asked to decontaminate the house. The company advised discarding the carpet, couch, and curtains and using gaseous ozone for all rooms of the house. The rooms were treated one after the other. Metal objects were temporarily put in another room. An ozone generator and ventilators were placed in the house to circulate the ozone, which is heavier than air. The generator produced approximately 35 g of ozone during 10 hours and was removed after 24 hours. The concentration of ozone was estimated at 12 ppm but was not measured. Each room was hermetically closed during the decontamination period and was subsequently thoroughly ventilated. The nurse, her 2 children, and the cat stayed with relatives for a week. Then the nurse was treated again. Two days after the house was cleaned, several specimens for culture were obtained from the house and the nurse. All yielded negative results, and the nurse started working again in April 2003. Swab specimens of the nose, throat, perineum, and skin lesions were obtained monthly until April 2004 and again in September 2005. All cultures remained negative for MRSA. The cost of this decontamination procedure was €2,000 (approximately \$2,400: salvage company, €1,500; discarded furniture, €500), which was paid by the hospital.

DISCUSSION

It is difficult to eradicate MRSA from a carrier with eczema, especially when present on the hands. The risk of MRSA spreading into the environment is significant because of the high shedding of skin flakes. If eczema is in remission and multiple courses of eradication therapy fail, the most likely cause is reinfection from family members, pets, or the home environment. The last possibility appears most plausible in this case, because the family members and pet were free of MRSA. This means that the staphylococci should have survived approximately 6 weeks in the home environment (Figure). Studies have shown that some MRSA isolates can indeed survive in dust or on synthetics for more than 5 weeks.^{7,8} Environmental MRSA eradication should be carefully planned, and the choice of the method for disinfection of rooms and furniture needs to be considered. Commonly used hospital disinfectants, such as ethanol, chlorine, and disinfectants that are less often used in The Netherlands, such as phenolics and quaternary ammonium compounds, are not appropriate for use with house furniture.

Two studies have described decontamination of the home environment for refractory MRSA carriage in healthcare

TABLE. Results of Cultures of Specimens Obtained From the Home Environment Before Ozone Disinfection

Room	Proportion (%) of cultures positive for MRSA	Items contaminated with MRSA
Living room	9/14 (64)	Armchair, carpet, cat's scratching post, curtains, piano, remote control, and telephone
Kitchen	0/1 (0)	None
Nurse's bedroom	1/4 (25)	Curtain
Son's bedroom	0/3 (0)	None
Daughter's bedroom	0/4 (0)	None
Bathroom	1/4 (25)	Shower mat
Toilet	0/2 (0)	None
Overall	11/32 (34)	...

NOTE. MRSA, methicillin-resistant *Staphylococcus aureus*.

workers.^{9,10} Allen et al.⁹ used a general-purpose detergent to thoroughly clean all hard furnishings, whereas all carpets and soft furnishings were steam-cleaned. Masterton et al.¹⁰ stated that the house was thoroughly vacuumed and damp dusted. In both situations, some of the old furniture was replaced, and the hospital employee was treated together with MRSA-colonized family members. All remained free of MRSA.

Ozone is often used as a disinfectant in the pharmaceutical and food industry and as a disinfectant of water and contaminated cloths. It is the treatment of choice to clean a house after a fire, to eliminate the foul burnt smell. Only a few studies describe possible medical applications of ozone,^{2,3} because it is toxic, necessitating respiratory protection for workers, and as a potent oxidizer is detrimental to metals. Ozone oxidizes the bacterial cell wall and cytoplasmic membrane, and fungi are equally susceptible. The dose response for microorganism inactivation is in the following order (low to high dose): gram-negative bacteria, vegetative gram-positive bacteria, yeasts, molds, and *Bacillus* spores.^{5,6} The ozone concentration necessary to kill MRSA appears to be higher than that needed to kill methicillin-sensitive *S. aureus*.^{2,4} Berrington and Pedler² tested the effect of gaseous ozone on MRSA in hospital rooms. They found that not all places in the room became free of MRSA and therefore concluded that this method was inadequate for decontamination. However, they ran the ozone generators for only 4-7 hours. On the basis of the experience of the salvage company and the favorable result in the present case, it appears wise to use generators for 10 hours, along with devices to circulate the ozone. The latter are necessary to disperse the gas equally, because gaseous ozone is heavier than air. All rooms should be tightly sealed to prevent loss of ozone. After decontamination, specimens for screening cultures should be collected. During the decontamination period, all inhabitants need to be accommodated elsewhere and MRSA carriers must be treated to prevent reintroduction of MRSA.

The cost of ozone cleaning and disinfection was €2,000 (approximately \$2,400). In 1997, Allen et al.⁹ reported the cost for cleaning, laundering, and replacement of furnishings to be approximately £2,000 (approximately \$3,500).

In conclusion, we describe how environmental screening is essential for investigating refractory MRSA carriage, even in the presence of a risk factor such as eczema. Furthermore,

we describe the successful use of gaseous ozone to eradicate MRSA from a widely contaminated home environment.

ACKNOWLEDGMENTS

We thank the nurse and her family, for their cooperation; Mr. A. de Reus and Mr. E. Meijer, for advice; Dr. R. Behrens, for critical review of the text; and the National Institute of Public Health and the Environment (Bilthoven), for phage typing of the strain.

From the Departments of Occupational Health (H.E.L.d.B) and Medical Microbiology (C.M.v.E.-D., C.M.F.v.R.-V., L.S.), Academic Medical Center, Amsterdam, The Netherlands.

Address reprint requests to Lodewijk Spanjaard, MD, PhD, Laboratory of Bacteriology, Academic Medical Center, L-1-243, P.O. Box 22660, 1100 DD Amsterdam, The Netherlands (L.Spanjaard@amc.uva.nl).

Received March 18, 2005; accepted March 18, 2006; electronically published September 21, 2006.

© 2006 by The Society for Healthcare Epidemiology of America. All rights reserved. 0899-823X/2006/2710-0017\$15.00.

REFERENCES

1. Tiemersma EW, Bronzwaer SL, Lyytikainen O, et al. Methicillin-resistant *Staphylococcus aureus* in Europe, 1999-2002. *Emerg Infect Dis* 2004; 10: 1627-1634.
2. Berrington AW, Pedler SJ. Investigation of gaseous ozone for MRSA decontamination of hospital side-rooms. *J Hosp Infect* 1998; 40:61-65.
3. Cardoso CC, Fiorini JE, Ferriera LR, Gurjao JW, Amaral LA. Disinfection of hospital laundry using ozone: microbiological evaluation. *Infect Control Hosp Epidemiol* 2000; 21:248.
4. Yamayoshi T, Tatsumi N. Microbicidal effects of ozone solution on methicillin-resistant *Staphylococcus aureus*. *Drugs Exp Clin Res* 1993; 19:59-64.
5. Moore G, Griffith C, Peters A. Bactericidal properties of ozone and its potential application as a terminal disinfectant. *J Food Prot* 2000; 63: 1100-1106.
6. Li CS, Wang YC. Surface germicidal effects of ozone for microorganisms. *AIHA (Fairfax, VA)* 2003; 64:533-537.
7. Neely AN, Maley MP. Survival of enterococci and staphylococci on hospital fabrics and plastic. *J Clin Microbiol* 2000; 38:724-726.
8. Wagenvoort JH, Penders RJ. Long-term in-vitro survival of an epidemic MRSA phage-group III-29 strain. *J Hosp Infect* 1997; 35:322-325.
9. Allen KD, Anson JJ, Parsons LA, Frost NG. Staff carriage of methicillin-resistant *Staphylococcus aureus* (EMRSA 15) and the home environment: a case report. *J Hosp Infect* 1997; 35:307-311.
10. Masterton RG, Coia JE, Notman AW, Kempton-Smith L, Cookson BD. Refractory methicillin-resistant *Staphylococcus aureus* carriage associated with contamination of the home environment. *J Hosp Infect* 1995; 29: 318-319.